

**Physician Information:**

Jack Smith, M.D.  
Sunshine Dermatology Center  
Anytown, NC 22222  
Phone: 999-999-9999

CLIA # 34D2081709

Medical Director: Garron J. Solomon, M.D.

**PATHOLOGY REPORT**

<b>Patient:</b>	<b>Jones, Tommy L.</b>	<b>Case Number:</b>	<b>D15-00006</b>
DOB/Age:	1/10/1938 (77 years)	Date Collected:	01/12/2015
MRN:	12456	Date Received:	01/12/2015
Phone #:	919-563-1485	Date Reported:	01/14/2015

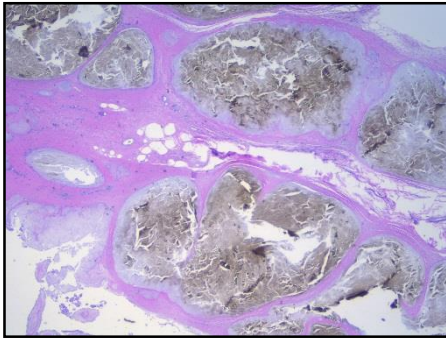
**CLINICAL HISTORY:**

rule out tophus

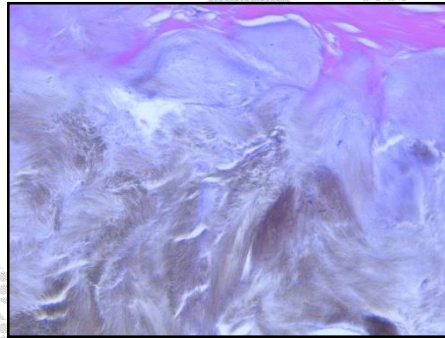
**DIAGNOSIS:**

Mass, Left Toe (Punch):  
**TOPHACEOUS GOUT**

Images are for illustrative purposes only and should not be used as diagnostic tools



Multiple nodular deposits are seen within dense fibrous connective.



The deposits are composed of brown needle-shaped crystals and amorphous pink material.



Urate crystals are seen under polarized light.

**MICROSCOPIC DESCRIPTION:**


The sections show large nodular aggregates of acellular material containing brown needle-shaped crystals and amorphous pink material, surrounded by dense fibrosis and rare foreign body-type giant cells. The sections show large nodular aggregates of acellular material containing brown needle-shaped crystals and amorphous pink material, surrounded by dense fibrosis and rare foreign body-type giant cells. The crystals exhibit negative birefringence under polarized light.

**GROSS DESCRIPTION:**

Received in formalin and labeled with the patient's name and "Left Toe" is a punch biopsy of skin measuring 0.6 x 0.6 x 1.0 cm. The specimen is bisected and entirely submitted in 1 cassette labeled A. Due to the loss of elastic tension and to formalin shrinkage, the measurements in the laboratory description may be less than those taken at the time of surgical removal. gm/GJS

CPT CODES: 88305

ICD CODES: 274.9

**ELECTRONICALLY SIGNED BY:****Garron J. Solomon, M.D.****01/14/2015 at 2:35 pm**