

PATHOLOGY REPORT

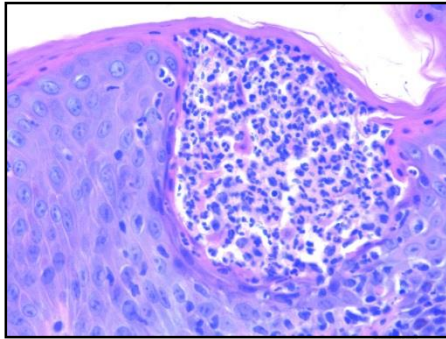
Patient:	Smith, Tommy R.	Case Number:	D15-00005
DOB/Age:	1/10/2002 (13 years)	Date Collected:	01/12/2015
MRN:	12456	Date Received:	01/12/2015
Phone #:	919-563-1485	Date Reported:	01/14/2015

CLINICAL HISTORY:
rule out arthropod bite

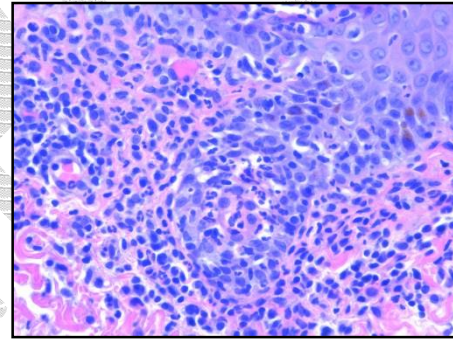
DIAGNOSIS:

Skin, Right Arm (Punch):
MILIARIA PUSTULOSA

Images are for illustrative purposes only and should not be used as diagnostic tools



A subcorneal pustule is pictured here.



Neutrophils are seen within an acrosyringium.

MICROSCOPIC DESCRIPTION:

The sections show a superficial perivascular infiltrate accompanied by neutrophils within acrosyringia and surmounted by subcorneal pustules. PAS-D stain is negative for fungi.

GROSS DESCRIPTION:

Received in formalin and labeled with the patient's name and "Right Arm" is a punch biopsy of skin measuring 0.3 x 0.3 x 0.4 cm. The specimen is inked in black and entirely submitted in 1 cassette labeled A. Due to the loss of elastic tension and to formalin shrinkage, the measurements in the laboratory description may be less than those taken at the time of surgical removal. gm/GJS

CPT CODES: 88305, 88312
ICD CODES: 705.1

ELECTRONICALLY SIGNED BY: *Garron J. Solomon, M.D.*

Garron J. Solomon, M.D.
01/14/2015 at 2:35 pm